



Contents lists available at ScienceDirect

Toxicon

journal homepage: www.elsevier.com/locate/toxicon

Review

Disease-oriented approach to botulinum toxin use

Joseph Jankovic*

Parkinson's Disease Center and Movement Disorders Clinic, Department of Neurology, Baylor College of Medicine, 6550 Fannin, Suite 1801, Houston, TX 77030, USA

ARTICLE INFO

Article history:

Received 30 October 2008

Accepted 28 November 2008

Available online 6 December 2008

Keywords:

Blepharospasm
 Botulinum toxin
 Bruxism
 Camptocormia
 Constipation
 Dystonia
 Parkinson disease
 Sialorrhea

ABSTRACT

Botulinum toxin (BoNT) has been used for over a quarter of century for the treatment of well over 100 different indications. Many of the symptoms for which BoNT has been found to be effective occur in a variety of neurological disorders. One neurodegenerative disorder in which BoNT has been used extensively to treat various symptoms is Parkinson's disease (PD). This review will highlight the following therapeutic applications of BoNT in conditions associated with PD: limb dystonia, blepharospasm and lid apraxia, bruxism, cervical dystonia (anterocollis), camptocormia, hand and jaw tremor, rigidity (painful shoulder), freezing of gait, sialorrhea, dysphagia (achalasia), seborrhea, hyperhidrosis, overactive bladder, and constipation.

© 2008 Elsevier Ltd. All rights reserved.

1. Introduction

The application of botulinum toxin (BoNT) as a therapeutic modality has expanded markedly over the past quarter of century. Initially used by specialists in neurology (movement disorders) and ophthalmology (strabismus), BoNT has been subsequently used in nearly all specialties of medicine, including psychiatry, orthopedics and sports medicine, otolaryngology, pediatrics, gastroenterology, urology, pain specialists, dermatology, and plastic surgery (Truong and Jost, 2006; Jankovic et al., 2008). In addition, neuroscientists and other basic scientists are using BoNT to study its mechanism of action, as a result of which our knowledge of BoNT as a molecule has increased exponentially.

There are several diseases in which troublesome symptoms, such as involuntary spasms or movements, hyposecretory or other autonomic dysfunctions, and other problems become amenable to BoNT treatment. Such disease-oriented application of BoNT has been successfully used in cerebral palsy and a variety of neurodegenerative

disorders. Parkinson disease (PD), the second most common neurodegenerative disorder, has been selected for this review to illustrate how disease-related symptoms may be effectively relieved with BoNT. Manifested by dozens of motor and non-motor symptoms that can impair activities of daily living, PD can seriously impact the quality of life of those afflicted with this disease (Jankovic, 2008). While most of the motor symptoms, particularly the cardinal features of PD, such as tremor, bradykinesia, rigidity and gait difficulty, improve with dopaminergic and other therapeutic, including surgical, strategies, many troublesome symptoms do not respond to conventional treatments (Diamond and Jankovic, 2006). In this review, we will briefly describe the use of BoNT in the treatment of the following PD-related disorders: limb dystonia, blepharospasm and apraxia of eyelid opening, bruxism, cervical dystonia (anterocollis), camptocormia, hand and jaw tremor, rigidity (painful shoulder), freezing of gait, sialorrhea, dysphagia (achalasia), seborrhea, hyperhidrosis, overactive bladder, and constipation (Table 1) (Sheffield and Jankovic, 2007). We will use the generic term botulinum toxin or BoNT, but the brand names, such as Botox[®], Dysport[®] and Xeomin[®], all BoNT type A (BoNT/A)

* Tel.: +1 713 798 5998; fax: +1 713 798 6808.

E-mail addresses: josephj@bcm.edu, josephj@bcm.tmc.edu

Table 1

Botulinum toxin in the treatment of symptoms associated with Parkinson's disease.

Dystonia
<ul style="list-style-type: none"> • Blepharospasm – lid apraxia • Bruxism • Limb – striatal hand/foot, levodopa-related dystonia • Cervical dystonia (anterocollis) • Camptocormia
Tremor – hand, jaw
Rigidity (painful shoulder)
Freezing of gait
Sialorrhea
Dysphagia (achalasia)
Seborrhea
Hyperhidrosis
Overactive bladder
Constipation

preparations, or Myobloc[®] (NeuroBloc[®]), a BoNT/B, will be identified whenever appropriate as properties and dosages are often unique to that product. While the intent of BoNT treatment is not only to improve the specific symptom but the patient's quality of life, it is important to point out that the overall outcome of BoNT treatment depends not only on selection of the appropriate target, preparation and dosage, but also on the injection technique, and many other factors (Lim and Seet, 2008).

2. Dystonia

Dystonia, a syndrome characterized by sustained muscle contraction associated with twisting, repetitive, and patterned movements or abnormal postures, has been treated with BoNT for the past quarter of century (Jankovic, 2006b). One form of focal dystonia, blepharospasm, was the first indication for which BoNT was approved by the Food and Drug Administration (FDA) (Jankovic and Orman, 1987). Blepharospasm can occur as a form of focal primary dystonia, without an identifiable cause (idiopathic or essential blepharospasm), or it may be due to a variety of etiologies including PD (Hallett et al., 2008). Different forms of dystonia may be present in up to 60% of patients with PD, particularly those with early onset (Jankovic and Tintner, 2001). In addition, dystonia may occur as one of several motor complications of levodopa therapy (Jankovic and Stacy, 2007).

2.1. Blepharospasm and lid apraxia

Blepharospasm is an involuntary, forceful eye closure, considered to be a form of dystonia (Hallett et al., 2008). Blepharospasm usually occurs in more advanced stages of PD; when it occurs alone it rarely leads to PD (Soonawala et al., 1999). Although it may accompany PD, the presence of blepharospasm should raise the possibility of atypical parkinsonism, such as progressive supranuclear palsy, in

which blepharospasm is more common (Azher and Jankovic, 2008). When seen in the setting of parkinsonism, blepharospasm is often associated with apraxia of eyelid opening. Attributed to a variety of possible mechanisms, such as focal dystonia, levator inhibition, abnormal contraction in the pretarsal orbicularis oculi, or eyelid freezing (analogous to freezing of gait, described below), the pathophysiology of lid apraxia is not well understood (Hallett et al., 2008; Elston, 1992; Krack and Marion, 1994).

The long-term experience with BoNT in the treatment of blepharospasm has provided evidence in support of the efficacy and safety of this treatment in patients with blepharospasm (Jankovic, 2004; Mejia et al., 2005; Kenney and Jankovic, 2008). Despite the extensive literature on BoNT in blepharospasm, an evidence-based review by the Therapeutics and Technology Assessment Subcommittee of the American Academy of Neurology (AAN) concluded that there is only level B (probably effective) evidence for its efficacy, and recommended that “BoNT injection should be considered as a treatment option for blepharospasm” (Simpson et al., 2008). This study involved 300 patients with blepharospasm, 256 of whom completed the trial (Roggenkamper et al., 2006). The primary outcome was the change from baseline in the sum score of the Jankovic Rating Scale (JRS). The adjusted mean change in the JRS was –2.90 for the NT 201 and –2.67 for the Botox[®] group. The frequency of ptosis, the most common adverse effect, was 6.1% and 4.5%, respectively. When compared to Botox[®], both products were found to be equally effective with no difference in adverse effects. The level B recommendation was supported by two Class II studies, both utilizing Botox[®] (Jankovic and Orman, 1987; Girlanda et al., 1996). One Class I study, which compared NT 201 (Xeomin[®]) with Botox[®] concluded that the two drugs are similar in their effects on blepharospasm (Roggenkamper et al., 2006). The likely reason for the lack of optimal evidence supporting BoNT use in blepharospasm is that the robust benefits observed in the initial open-label studies, coupled with the lack of alternative therapies, discouraged other and better controlled clinical trials.

Another Class I study, published after the above AAN report (Simpson et al., 2008), was a multicenter, clinical, fixed-dose, trial comparing Dysport[®] (40, 80, and 120 U/eye) with placebo (in a 3:1 randomization ratio) in 119 patients with blepharospasm, 85 of whom completed the 16-week study (Truong et al., 2008). There was a robust improvement in Dysport[®] arms compared to placebo in several measures. Overall, 80 U of Dysport[®] seemed to provide best balance between efficacy and adverse effects, such as ptosis, blurred vision, diplopia, tearing, and dry eyes. A Chinese formulation of BoNT/A, termed Prosigne, has been found in a double-blind, controlled, crossover trial to be similar in its safety and efficacy to Botox[®] when evaluated in 6 patients with blepharospasm and hemifacial spasm (Rieder et al., 2007). In addition to BoNT/A, BoNT/B has also been used successfully in the treatment of blepharospasm (and hemifacial spasm), although double-blind controlled studies in these disorders are lacking (Colosimo et al., 2003).

Several studies reported improvement in apraxia of eyelid opening, particularly if associated with or triggered

by blepharospasm, when the pretarsal orbicularis oculi was injected (Aramideh et al., 1995; Forget et al., 2002; Jankovic, 1995; Lepore et al., 1995; Cakmur et al., 2002; Dutton and Fowler, 2007). Injection of the pretarsal portion of the eyelid or pars ciliaris (also known as Riolan's muscle) at the lid margin seems critical for the treatment to be effective in apraxia of eyelid opening (Inoue and Rogers, 2007).

Whether BoNT is used for blepharospasm with or without PD or with or without apraxia of eyelid opening, the average latency from the time of the injection to the onset of improvement is 3–5 days and the duration of benefit is usually 3–4 months. Frowning without blepharospasm, as a manifestation of upper facial dystonia, often seen in parkinsonian patients, particularly those with progressive supranuclear palsy, can be also effectively treated with BoNT (Hirota et al., 2008).

2.2. Bruxism

Bruxism is an involuntary movement disorder, manifested by jaw clenching (trismus), tooth gnashing and/or grinding, that can be classified as a form of focal (oromandibular) dystonia. In contrast to most other dystonias, bruxism occurs not only in awake individuals, but also during sleep (nocturnal bruxism) (Bader and Lavigne, 2000). If left untreated it can lead to tooth destruction, temporomandibular dysfunction (e.g., jaw pain or movement limitation), headaches, and the disruption of the bed partner's sleep due to the grinding sounds. Bruxism may be associated with or caused by parkinsonism, Huntington's disease, Tourette's syndrome, cranial dystonia, tardive dyskinesia, depression, REM behavior disorder, the use of medications, such as levodopa, neuroleptics, amphetamines, and selective serotonin reuptake inhibitors such as fluoxetine, sertraline, fluvoxamine and paroxetine, and substance abuse (e.g., cocaine).

While the use of night guards and other dental appliances and procedures may be helpful, there is no effective treatment available for bruxism. In one of our studies, 18 patients with severe bruxism were injected with a mean dose of 61.7 ± 11.1 U (Botox) into each masseter during 123 treatment visits (Tan and Jankovic, 2000). The mean peak effect on a scale of 0–4 (in which 4 is equal to total abolishment of grinding) was 3.4 ± 0.9 . Only one subject (5.6%) reported transient dysphagia. In addition to idiopathic or dystonic bruxism, we have used BoNT in patients with Huntington's disease, Tourette's syndrome, and a variety of other movement and neurological disorders. When administered by skilled practitioners BoNT is a safe and effective treatment for people with severe bruxism.

2.3. Limb dystonia

Although dystonia in PD involves the complete spectrum of focal dystonias including blepharospasm, oromandibular dystonia usually manifested by bruxism, the most typical dystonia present at onset of PD is foot dystonia, which may be the initial manifestation of the disease (Jankovic, 2005). Abnormal postures, such as the "striatal foot", with unilateral equinovarus dystonic posture of the foot and extension of the great toe, and "striatal hand",

with flexion of the metacarpophalangeal joints and extension of the interphalangeal joints, may be seen in up to 10% of untreated patients with advanced disease (Ashour et al., 2005). It is not clear whether these deformities are forms of focal dystonia or represent joint and skeletal abnormalities associated with PD (Ashour and Jankovic, 2006). Since levodopa has a variable effect on these deformities, BoNT has been used to effectively correct the abnormal postures in cases in which the abnormal involuntary contractions have not yet progressed to fixed contractures (Giladi et al., 1994).

BoNT has been used effectively in treating painful foot dystonia, typically presenting in patients with PD as a form of levodopa-related, peak-dose dyskinesia or wearing off-dystonia (Jankovic and Stacy, 2007). In an open-label pilot study, PD patients with "off" painful dystonia were treated injected in the tibialis posterior, tibialis anterior, gastrocnemius, flexor digitorum longus, and extensor hallucis longus muscles with a median dose 40 U (Botox) in each muscle distributed in two sites (Pacchetti et al., 1995). The pain improved within 10 days in all patients, and 7 patients noted an improvement of foot posture on walking. Patients with PD, progressive supranuclear palsy, corticobasal degeneration and other forms of parkinsonism (or stroke-related hemiplegia) occasionally develop secondary fixed dystonia of the hand ("dystonic clenched fist") which may benefit in terms of pain and hygiene from local BoNT injections (Cordivari et al., 2001).

BoNT has been established as an effective treatment modality in mobile forms of dystonia, but it may be at least partially effective in some patients with striatal hand and striatal foot and toe deformities, particularly when not accompanied by fixed contractures (Jankovic, 2004; Giladi et al., 1994).

2.4. Cervical dystonia

BoNT has long been considered the treatment of choice in patients with cervical dystonia (Jankovic, 2006a; Molho et al., 2008). Based on a review of seven Class I studies, the AAN report concluded that "BoNT is established as safe and effective for the treatment of cervical dystonia" (Simpson et al., 2008). There is, however, no Class I evidence that BoNT is effective in cervical dystonia associated with PD. While patients with PD often have abnormal neck postures, there is some controversy whether this abnormality is due to cervical dystonia, rigidity, a combination of the two or some other mechanisms (Jankovic and Tintner, 2001; Ashour and Jankovic, 2006; van de Warrenburg et al., 2007). Furthermore, neck flexion (anterocollis), the most common abnormal neck posture associated with parkinsonism, particularly PD and multiple system atrophy, is often excluded from cervical dystonia trial studies of BoNT. This is apparently due to the belief that anterocollis is usually difficult to treat with BoNT and is often associated with dysphagia due to bilateral injection of sternocleidomastoid and scalenus muscles. We have found that when the involved muscles are injected with an appropriate dosage that the anterocollis can be successfully treated with minimal or no adverse effects (Figs. 1 and 2). In some cases of anterocollis, the longus colli may be involved and

their injection with imaging guidance can produce safe and effective relief of the neck flexion (Herting et al., 2004). We also found in early stages of development of BoNT in the treatment of cervical dystonia, that contractions of the submental muscle complex may contribute to anterocollis, in many cases, an injection of this region, with or without concomitant injection of the sternocleidomastoid and scalenus muscles, often results in marked improvement in the abnormal neck flexion. This approach, however, must be undertaken with great caution as dysphagia and aspiration pneumonia may complicate this treatment. In contrast to anterocollis, retrocollis is relatively safe and easy to treat by injecting the posterior neck muscles (Papapetropoulos et al., 2007).

2.5. Axial dystonia and camptocormia

Axial dystonia, which may be manifested as cervical dystonia in a form of torticollis, laterocollis or anterocollis (bent spine) or an abnormal posture of the trunk causing scoliosis, kyphosis, camptocormia, pisa syndrome, or any combination of these abnormal postures, is a common cause of physical and social handicap in patients with PD

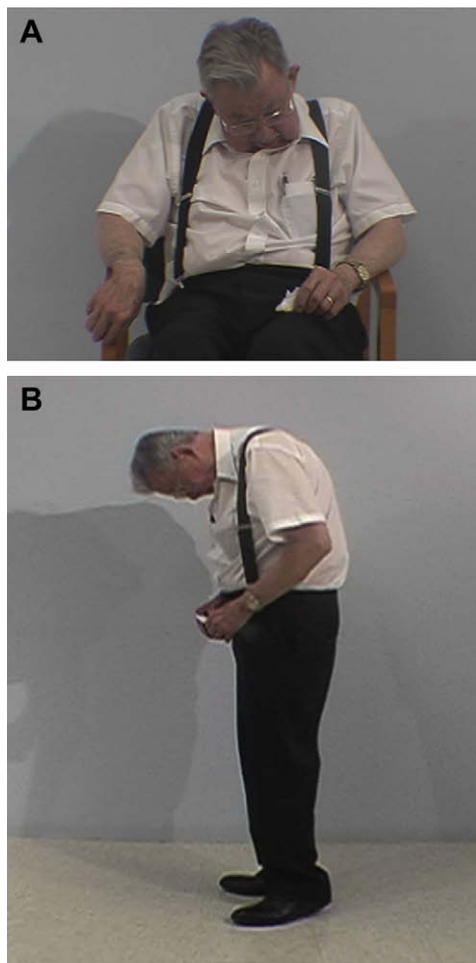


Fig. 1. (A, B) Patient with PD and severe anterocollis (before BoNT).



Fig. 2. Patient's anterocollis markedly improved within 4 weeks after treatment with BoNT (Botox® 75 U in the right and 50 U in the left scalene).

(Jankovic, 2008; Ashour and Jankovic, 2006). BoNT has been used in the treatment of axial postural abnormalities, including scoliosis, with variable success. In one study, six of nine patients with lateral axial dystonia (scoliosis) reported benefit as indicated by improvement in the Trunk Dystonia Disability Scale and visual analog scale after EMG-guided injection of 500 U of Dysport® into paraspinal muscles at the level of L2–L5 on the side of the trunk flexion (Bonanni et al., 2007).

Originally considered a psychogenic disorder in World War I and II soldiers, camptocormia, manifested by an abnormal posture of the trunk with marked flexion of the thoracolumbar spine, is associated with multiple etiologies, such as PD, dystonia, and possible extensor myopathies (Azher and Jankovic, 2005; Lepoutre et al., 2006; Bloch et al., 2006; Melamed and Djaldetti, 2007). The abnormal flexion of the trunk is often associated with a subjective feeling of “pulling” and clinical or EMG evidence of active contraction of the rectus abdominus. Despite the severe flexion of the trunk, patients with dystonic camptocormia can straighten their trunk when lying down or when they climb up the wall with their hands.

The conventional anti-PD medications and anti-spasticity agents are rarely beneficial in the treatment of camptocormia and, therefore BoNT and other strategies including deep brain stimulation (Hellmann et al., 2006) have been investigated in the treatment of this troublesome condition. In the report by Azher and Jankovic (2005), 9 of 11 patients received BoNT injections (300–600 U of Botox® per treatment visit) into the rectus abdominus for their camptocormia with notable improvement (Figs. 3 and 4). This effect lasted for about three months after each injection with a mean duration of maximal response in three patients of 10 ± 6 weeks. In contrast to the benefits observed in camptocormia with injection of the rectus abdominus, ultrasound-guided injection of the iliopsoas muscle with BoNT was not effective (von Coelln et al., 2008).

3. Tremor

Although hand rest tremor is one of the most recognizable features of PD, it is its re-emergence when the hand



Fig. 3. Patient with PD and camptocormia.

is held in a postural position, the so called re-emergent tremor, that often interferes with the ability to hold objects such as newspaper or a cup, and is more troublesome for patients with PD than the typical rest tremor (Jankovic et al., 1999). While levodopa and other anti-PD treatments are usually effective in improving this cardinal feature of PD, other treatment such as BoNT and deep brain stimulation must be considered in patients who fail to obtain satisfactory relief (Diamond and Jankovic, 2006).



Fig. 4. Patient's camptocormia markedly improved after treatment with BoNT (Botox® 200 U in each rectus abdominus).

Two double-blind, placebo-controlled studies demonstrated that BoNT was safe and effective in the treatment of essential tremor (Jankovic et al., 1996; Brin et al., 2001). Both studies showed reduction in the amplitude of the tremor with BoNT, but the treatment was complicated by high frequency of extensor finger weakness. As a result, we have modified our protocol and have markedly decreased the dosage in the forearm extensor muscles or completely omit injections into these muscles. This has resulted in marked reduction of finger weakness without compromising the benefits.

Some studies have also showed benefit in patients with other types of tremor, including PD-related tremor (Jankovic and Schwartz, 1991; Trosch and Pullman, 1994; Henderson et al., 1996). In one open-label study (Trosch and Pullman, 1994) of severe hand tremors, BoNT was injected into forearm and arm muscles in 26 patients of which 12 had PD and 14 had essential tremor. At six weeks after injection, 10 patients (38%; five PD and five essential tremor) reported moderate to marked subjective improvement in functional benefit. Only patients with essential tremor, however, showed statistically significant improvement when pre- and post-injection scores were compared on the Webster Tremor and Global Disability Scales. In 2 of 12 (17%) PD and 3 of 14 (21%) ET patients, more than 50% reduction measured by accelerometry was found after BoNT injections. Further studies are needed to demonstrate efficacy of BoNT in patients with PD-related tremor. Such studies may also provide insights how to improve the treatment protocol. For example, in some patients with prominent pronating–supinating component of the hand tremor, the biceps muscles may need to be injected in addition to the wrist and finger flexors.

In addition to hand and foot tremor, PD patients often experience tremors in the lips, chin and lower jaw (Hunker and Abbs, 1990; Erer and Jankovic, 2007). In an open-label pilot study (Schneider et al., 2006), Dysport® was injected with a mean dosage of 53 U (range: 30–100 U) into each masseter muscle with marked improvement in jaw tremor in 3 PD patients, demonstrated by subjective and clinical outcome assessments including video recording before and at 4–9 weeks after injections. The effect lasted 3–4 months in each patient, at which point injections were repeated with the same dosages with similar benefit in all three patients. The patients experienced no side effects including no complaints of dry mouth.

4. Freezing of gait

Freezing of gait (FOG) is a debilitating phenomenon in which a patient is suddenly unable to initiate gait or continue ongoing movements, particularly walking through a narrow passage, turning, or stressful situations (Jankovic, 2008; Giladi et al., 2001b). The mechanism of FOG is not well understood but since it responds poorly to levodopa, this PD symptom has been thought to be mediated by non-dopaminergic mechanisms, including damage to the brainstem pedunculopontine nucleus (Kuo et al., 2008). Denny Brown (1958) proposed that freezing represented a dystonic, disinhibited foot grasp, but this hypothesis is not universally accepted.

The possibility that FOG is partly due to involuntary contractions in distal legs and feet has led to clinical trials of BoNT in the treatment of this disabling symptom in patients with PD and other parkinsonian disorders. While the initial reports were encouraging (Giladi and Honigman, 1997; Giladi et al., 2001a), subsequent studies showed little or no benefit of BoNT on FOG (Fernandez et al., 2004; Gurevich et al., 2007; Wieler et al., 2005). In a pilot study of 10 parkinsonian patients (Giladi et al., 2001a) up to 300 U of BoNT (Botox[®]) was injected into the gastrocnemius and soleus muscles of each patient, bilaterally in half and unilaterally in half of the subjects. Some of these patients also had foot dystonia and they were additionally injected in other muscles including the tibialis posterior and extensor hallucis longus muscles. One patient was injected in a single blind fashion with saline after he had an initial good response to BoNT. Response of FOG was assessed by patients with a subjective rating from worsening (−1) to marked improvement (+3). Seven patients reported improvement in FOG severity in 15 out of 17 therapeutic sessions. There was marked (+3) improvement in four patients (40%) in five sessions, and two patients reported no effect in 2 sessions. The patient who was injected in a single blind fashion did not respond to saline injections but improved with BoNT treatment. The mean duration of improvement was six weeks (range 1–12 weeks) with definite deterioration afterward.

These encouraging results, however, could not be reproduced by subsequent double-blind, placebo-controlled studies (Fernandez et al., 2004; Gurevich et al., 2007; Wieler et al., 2005). In the first study (Fernandez et al., 2004), 18 patients with PD and FOG were randomized to receive 5000 U of botulinum toxin B (Myobloc[®]) treatment or placebo into the soleus–gastrocnemius complex of the clinically most affected leg or the side where PD symptoms first occurred if both legs were affected equally. Using a seven point Clinical Global Impression Scale, only one patient was much improved; there was no significant difference between the treatment and placebo groups in the UPDRS parts II and III concerned with freezing, a visual analog scale of improvement, or the Webster Step–Seconds Test. In the second study (Wieler et al., 2005), 12 subjects with PD and FOG were studied in a crossover design. A movement disorders specialist administered 200–300 U of BoNT/A with two injections into each of the medial and lateral heads of gastrocnemius and two into soleus under EMG guidance. Three subjects reported subjective improvement from BoNT with two reporting a decrease in FOG frequency, but there were no differences between the BoNT and placebo groups in any of the primary or secondary measures. A third double-blind, placebo-controlled study involving 11 patients with FOG also failed to show any benefit with BoNT injections into calf muscles and was terminated due to increased falls (Gurevich et al., 2007).

5. Sialorrhea

Sialorrhea (drooling), a common symptom of PD affecting approximately 75% of patients, can cause considerable social handicap, irritation of skin around the mouth,

infection and other problems (Jankovic, 2008). After collecting un-stimulated saliva over a 5-min period, patients with PD were found to produce less saliva than normal control subjects and the production of saliva did not correlate with the severity of PD; women with PD produced less saliva than men with PD (Proulx de Courval et al., 2005; Tumilasci et al., 2006). These findings suggest that sialorrhea in PD patients is not due to increased saliva production, but to dysregulation of salivary function possibly due to involvement of the salivary parasympathetic ganglia, coupled with impaired swallowing, possibly secondary to the involvement of motor nucleus of vagus, degeneration of the myenteric plexus in the esophagus, and flexed posture (Pinnington et al., 2000).

Among the treatments for sialorrhea in patients with PD, muscarinic antagonists, amantadine, and tricyclic antidepressants are frequently used (Tscheng, 2002), but several studies have provided evidence that BoNT may be the treatment of choice for sialorrhea associated with PD and other disorders with bulbar dysfunction, such as amyotrophic lateral sclerosis, cerebral palsy, posttraumatic encephalopathy, and bilateral strokes (Jost, 1999; Friedman and Potuliska, 2001; Mancini et al., 2003; Racette et al., 2003; Nóbrega et al., 2007; Ondo et al., 2004; Lagalla et al., 2006; Santamato et al., 2008; Molloy, 2007; Dogu et al., 2004; Pal et al., 2000). Ultrasound-guided injection may improve the efficacy of BoNT treatment for sialorrhea (Dogu et al., 2004).

In a double-blind, placebo-controlled study of 20 patients (14 with PD and six with multiple system atrophy) (Mancini et al., 2003), Dysport[®] 450 U was injected into the parotid and submandibular glands under ultrasound guidance. One week later the Dysport[®] group showed a significant ($p < 0.05$) reduction in drooling compared to both its own baseline value and to the placebo group as measured by drooling severity and frequency scales. No adverse events were reported during the study. In a study of a heterogeneous cohort of 32 patients with severe drooling (12 with bulbar amyotrophic lateral sclerosis, 12 with PD, 4 with multiple system atrophy, and 4 with corticobasal degeneration), patients were randomized into one of four treatment groups: placebo, 18.75 U, 37.5 U, or 75 U of BoNT (Lipp et al., 2003). BoNT was injected into each parotid gland with two injections: one injection into the mass of the gland and another into the adjacent part above the masseter muscle. Measurements were made objectively using dental rolls every four weeks. Subjective patient measurements included pressing a counter every time they did sialorrhea-related acts (e.g., wipe, spit, or intentionally swallow saliva) and assessing their quality of daily life. A significant ($p < 0.05$) saliva reduction of approximately 50% was observed with the 75 U BoNT group compared to placebo. Data from 24 patients showed that 12 of 18 BoNT-treated patients counted less drooling, but only the 75 U dose treated patients reached statistical significance ($p < 0.05$). None of the subjective measures showed significant differences between placebo and BoNT-treated patients. In another double-blind, randomized, placebo-controlled study, 32 patients with PD were randomly assigned to receive either 50 U of BoNT (Botox[®]) or 0.9% saline solution (placebo) into each parotid gland

(Lagalla et al., 2006). The BoNT-treated patients showed a significant ($p < 0.0001$) improvement in almost all subjective measures of drooling impact at the one month assessment compared to baseline, while patients in the placebo group remained unchanged. At one month post-treatment, 37% of BoNT-treated patients scored lower than 2 on the UPDRS-ADL drooling item, compared with 6% of patients in the placebo group. In 14 (88%) of the 16 BoNT-treated patients compared with only five (31%) of 16 placebo-treated patients, the patients declared that they were satisfied with their treatment and would be willing to receive repeated injections. Objective evaluation of saliva production showed that it was significantly ($p < 0.0001$) reduced after BoNT treatment, but did not change after placebo treatment.

In a pilot study with Myobloc[®] (Racette et al., 2003), nine subjects with parkinsonism were injected with 1000 U into each parotid gland for a total of 2000 U. Measurements included a subjective visual analog scale and weighing of dental pads placed in the mouth for 5 min. Three weeks after injections, patients reported subjective drooling using a visual analog scale. Subjective improvement averaged 61% and there was a non-significant trend toward a reduction in objectively measured saliva production. In a double-blind, placebo-controlled, parallel-group trial of 16 patients with PD a total of 2500 U of Myobloc[®] was injected into the parotid and submandibular glands (1000 divided at two sites into each parotid gland and 250 at one site into each submandibular gland) (Ondo et al., 2004). The injections were placed just dorsal to the masseter muscle (parotid gland) and one location just anterior and medial to the genu of the mandible (submandibular gland). Salivary gland imaging was also done using a standard method with IV injection of 99mTc-pertechnetate. At one month after injection, those randomized to receive Myobloc[®] reported a significant ($p < 0.05$) improvement on the global impression of change, Drooling Rating Scale, Drooling Severity and Frequency Scale and visual analog scale, compared to those receiving placebo. Baseline-quantified scintigraphy scans varied tremendously, but four of six subjects on active treatment showed a >33% reduction in tracer uptake (reduced saliva production), whereas only two of seven on placebo had a similar improvement. Other studies provided evidence that BoNT/B may be more effective than BoNT/A in treating sialorrhea as dry mouth was significantly more frequently noted in patients treated for cervical dystonia with BoNT/B as compared to BoNT/A (Tintner et al., 2005). Patients treated with Myobloc[®] had significantly less saliva production ($p < 0.01$) than those treated with Botox[®], but did not differ with respect to other tests of autonomic function including changes in blood pressure, heart rate and ocular function.

The overall results of these studies suggest the three types of BoNT, Botox[®], Dysport[®], Myobloc[®], are useful for the treatment of sialorrhea in PD. The potential adverse effects include dysphagia and xerostomia, but these and other side effects are transient and can be prevented with subsequent treatments by adjusting dosage or using different technique. The best dose and methodology (ultrasound guided or not and parotid vs. parotid and submandibular) still needs to be determined, but since “dry

mouth” is one of the most frequent complications of treatment with Myobloc[®], we consider this form of BoNT as the treatment of choice for sialorrhea. However, although clearly effective in the treatment of sialorrhea as well as other conditions, Myobloc[®] appears to be associated with relatively high antigenicity, particularly in patients who have developed blocking antibodies to BoNT/A (Jankovic et al., 2006).

6. Dysphagia (achalasia)

Swallowing difficulties (dysphagia) are well recognized in patients with PD and may in part contribute to sialorrhea, as noted above. Possible reasons for dysphagia in PD include: degeneration of the motor nucleus of vagus, Lewy bodies in myenteric plexus in the esophagus, flexed neck posture, and achalasia (Pinnington et al., 2000). Achalasia, manifested by repetitive, spontaneous contractions of the proximal esophagus and failure of the lower esophageal sphincter to relax during swallowing, has been documented in some patients with PD (Johnston et al., 2001). Several studies have demonstrated the beneficial effects of BoNT injections into the lower esophageal sphincter in the treatment of achalasia, particularly in patients who are not candidates for surgery or balloon dilatation (Blitzer and Brin, 1997; Eaker et al., 1997; Pasricha et al., 1995; Pohl and Tutuian, 2007; Schiano et al., 1998).

7. Seborrhea

Although there are no studies demonstrating efficacy of BoNT in seborrhea, a common dermatological disorder associated with PD, we have previously reported that BoNT is effective in the treatment of acne (Diamond and Jankovic, 2006). We postulated that BoNT inhibits comedogenesis by interrupting cholinergic transmission between autonomic nerve terminals and secretory glands or by some yet unknown anti-inflammatory effects. Since seborrheic dermatitis may be seen in conjunction with other skin diseases, such as rosacea, blepharitis or ocular rosacea, and acne vulgaris (Gupta et al., 2003), it is possible that PD-related seborrhea may also respond to BoNT.

8. Hyperhidrosis

Many patients with PD complain of excessive sweating and “drenching sweats” have been suggested as evidence of dysautonomia in PD. Sweating dysfunction, hyperhidrosis, and to a lesser extent hypohidrosis, were reported by 64% of patients with PD as compared to 12.5% of controls ($p < 0.005$) (Swinn et al., 2003). These symptoms did not correlate with the severity of the disease, but occurred most frequently during the “off” periods and during “on with dyskinesia” periods. Because the sudomotor skin response was reduced in the palms, axial hyperhidrosis has been suggested to be a compensatory phenomenon for reduced sympathetic function in the extremities (Schestatsky et al., 2006). Sweating may be a particularly troublesome symptom during wearing off (Pursiainen et al., 2007).

Although BoNT has not been studied in sweating disorders associated with PD, this treatment has been found to be effective in the treatment of essential hyperhidrosis. Essential hyperhidrosis, defined as excessive sweating of the palms, feet or axillae, affects about 2.5% of the population (Murray et al., 2007). Several well-designed trials have demonstrated efficacy of intradermal injection of BoNT in focal hyperhidrosis (Solish et al., 2007; Naumann et al., 2008). Based on a review of two Class I studies of BoNT in axillary hyperhidrosis, the Therapeutics and Technology Assessment Subcommittee of the AAN concluded that there is level A evidence for the recommendation that BoNT should be offered as a treatment option for axillary hyperhidrosis (Naumann et al., 2008).

9. Overactive bladder

BoNT is also being increasingly used in the treatment of bladder and other genitourinary disorders, often affecting patients with PD (Apostolidis and Fowler, 2008). One survey found that over one fourth of men with PD had urinary difficulty, particularly urinary urgency (Araki and Kuno, 2000). An increasing number of reports provide evidence that BoNT injections into the bladder wall is an effective treatment in increasing the bladder capacity, and improving urge and incontinence in patients with overactive bladder associated with neurogenic and idiopathic detrusor overactivity (Patel et al., 2006). Other genitourinary indications for BoNT treatment include voiding dysfunction due to benign prostatic hypertrophy (Chuang and Chancellor, 2006). Based on a review of two Class I studies of BoNT in neurogenic detrusor overactivity, the Therapeutics and Technology Assessment Subcommittee of the AAN concluded that there is level A evidence for the recommendation that BoNT should be offered as a treatment option for this urinary disorder (Naumann et al., 2008).

10. Constipation

Constipation, up to 5 times more common in PD than the general population, is regarded as one of the most troublesome non-motor symptoms of PD (Pfeiffer, 2003). The mechanism of constipation in PD is not well understood, but may be due to either slow-transit or to outlet obstruction, possibly related to involvement of the myenteric plexus in the intestinal wall (Sakakibara et al., 2003). Anismus (constipation due to functional obstruction at the pelvic outlet by paradoxical contraction of the striated sphincter muscles during defecation straining) has been suggested to represent a form of focal dystonia and has been considered as a possible etiology of constipation in PD (Mathers et al., 1988).

Several open-label studies demonstrated the beneficial effects of BoNT anal injections in the treatment of constipation associated with PD. In a pilot study involving 10 PD patients with isolated or prominent outlet-type constipation were injected with BoNT in the puborectalis muscle (two sites on either side of the muscle) under transrectal ultrasonographic guidance (Albanese et al., 2003). The total dose per session was 100 U. At one month

after treatment, anal tone, as assessed with anorectal manometry during straining, was reduced from 97.4 ± 19.6 mm Hg at baseline to 40.7 ± 11.5 mm Hg. In another open-label study of 10 of 18 PD patients with outlet constipation noted symptomatic improvement two months after 100 U of BoNT was injected using transrectal ultrasonography perineally into two sites on either side of the paradoxically contracting puborectalis muscle (Cadeddu et al., 2005). Anorectal manometry demonstrated decreased tone during straining from 96.2 ± 17.1 to 45.9 ± 16.2 mm Hg at one month evaluation, and to 56.1 ± 10.7 mm Hg at two months. Additional patients improved when they were re-injected with 200–300 U of BoNT. Further studies, particularly double-blind, placebo-controlled, trials are needed to confirm the efficacy and safety of BoNT in the treatment of PD-related constipation.

11. Conclusion

Botulinum toxin injections can play many useful roles in the treatment of patients with PD. Similar considerations might be given to difficult to treat symptoms in other neurological disorders.

Conflict of interest

The author has served as a consultant to and received research grants from Allergan, Merz and Dysport.

References

- Albanese, A., Brisinda, G., Bentivoglio, A.R., Maria, G., 2003. Treatment of outlet obstruction constipation in Parkinson's disease with botulinum neurotoxin A. *Am. J. Gastroenterol.* 98, 1439–1440.
- Apostolidis, A., Fowler, C.J., 2008. The use of botulinum neurotoxin type A (BoNTA) in urology. *J. Neural. Transm.* 115, 593–605.
- Araki, I., Kuno, S., 2000. Assessment of voiding dysfunction in Parkinson's disease by the international prostate symptom score. *J. Neurol. Neurosurg. Psychiatry* 68, 429–433.
- Aramideh, M., Ongerboer de Visser, B.W., Brans, J.W., Koelman, J.H., Speelman, J.D., 1995. Pretarsal application of botulinum toxin for treatment of blepharospasm. *J. Neurol. Neurosurg. Psychiatry* 59, 309–311.
- Ashour, R., Jankovic, J., 2006. Joint and skeletal deformities in Parkinson's disease, multiple system atrophy, and progressive supranuclear palsy. *Mov. Disord.* 21, 1856–1863.
- Ashour, R., Tintner, R., Jankovic, J., 2005. Striatal deformities of the hand and foot in Parkinson's disease. *Lancet Neurol.* 4, 423–431.
- Azher, S.N., Jankovic, J., 2005. Camptocormia: pathogenesis, classification, and response to therapy. *Neurology* 65, 355–359.
- Azher, S.N., Jankovic, J., 2008. Clinical aspects of progressive supranuclear palsy. In: Duyckaerts, C., Litvan, I. (Eds.), 3rd Series. *Handbook of Clinical Neurology*, 89. Elsevier, Amsterdam, The Netherlands, *Handb Clin Neurol*, pp. 461–473.
- Bader, G., Lavigne, G.J., 2000. Sleep bruxism: overview of an oromandibular sleep movement disorders. *Sleep Med. Rev.* 4, 27–43.
- Blitzer, A., Brin, M.F., 1997. Use of botulinum toxin for diagnosis and management of cricopharyngeal achalasia. *Otolaryngol. Head Neck Surg.* 116, 328–330.
- Bloch, F., Houeto, J.L., Tezenas du Montcel, S., et al., 2006. Parkinson's disease with camptocormia. *J. Neurol. Neurosurg. Psychiatry* 77, 1223–1228.
- Bonanni, L., Thomas, A., Varanese, S., Scorrano, V., Onofri, M., 2007. Botulinum toxin treatment of lateral axial dystonia in parkinsonism. *Mov. Disord.* 22, 2097–2103.
- Brin, M.F., Lyons, K.E., Doucette, J., Adler, C.H., Caviness, J.N., Comella, C.L., Dubinsky, R.M., Friedman, J.H., Manyam, B.V., Matsumoto, J.Y., Pullman, S.L., Rajput, A.H., Sethi, K.D., Tanner, C., Collier, W.C., 2001. A randomized, double masked, controlled trial of botulinum toxin type A in essential hand tremor. *Neurology* 56, 1523–1528.

- Cadeddu, F., Bentivoglio, A.R., Brandara, F., Marniga, G., Brisinda, G., Maria, G., 2005. Outlet type constipation in Parkinson's disease: results of botulinum toxin treatment. *Aliment. Pharmacol. Ther.* 22, 997–1003.
- Cakmur, R., Ozturk, V., Uzunel, F., Donmez, B., Idiman, F., 2002. Comparison of preseptal and pretarsal injections of botulinum toxin in the treatment of blepharospasm and hemifacial spasm. *J. Neurol.* 249, 64–68.
- Chuang, Y.C., Chancellor, M.B., 2006. The application of botulinum toxin in the prostate. *J. Urol.* 176, 2375–2382.
- Colosimo, C., Chianese, M., Giovannelli, M., Contarino, M.F., Bentivoglio, A.R., 2003. Botulinum toxin type B in blepharospasm and hemifacial spasm. *J. Neurol. Neurosurg. Psychiatry* 74, 687.
- Cordivari, C., Misra, P., Catania, S., Lees, A.J., 2001. Treatment of dystonic clenched fist with botulinum toxin. *Mov. Disord.* 16, 907–913.
- Denny Brown, D., 1958. The nature of apraxia. *J. Nerv. Ment. Dis.* 126, 9–31.
- Diamond, A., Jankovic, J., 2006. Botulinum toxin in dermatology – beyond wrinkles and sweat. *J. Cosmet. Dermatol.* 5, 169.
- Diamond, A., Jankovic, J., 2006. Treatment of advanced Parkinson's disease. *Expert Rev. Neurother.* 6, 1181–1197.
- Dogu, O., Apaydin, D., Sevim, S., Talas, D.U., Aral, M., 2004. Ultrasound-guided versus 'blind' intraparotid injections of botulinum toxin-A for the treatment of sialorrhoea in patients with Parkinson's disease. *Clin. Neurol. Neurosurg.* 106, 93–96.
- Dutton, J.J., Fowler, A.M., 2007. Botulinum toxin in ophthalmology. *Surv. Ophthalmol.* 52, 13–31.
- Eaker, E.Y., Gordon, J.M., Vogel, S.B., 1997. Untoward effects of esophageal botulinum toxin injection in the treatment of achalasia. *Dig. Dis. Sci.* 42, 724–727.
- Elston, J.S., 1992. A new variant of blepharospasm. *J. Neurol. Neurosurg. Psychiatry* 55, 369–371.
- Erer, S., Jankovic, J., 2007. Hereditary chin tremor in Parkinson's disease. *Clin. Neurol. Neurosurg.* 109, 784–785.
- Fernandez, H.H., Lannon, M.C., Trieschmann, M.E., Friedman, J.H., 2004. Botulinum toxin type B for gait freezing in Parkinson's disease. *Med. Sci. Monit.* 10, 282–284.
- Forget, R., Tozlovanu, V., Iancu, A., Boghen, D., 2002. Botulinum toxin improves lid opening delays in blepharospasm-associated apraxia of lid opening. *Neurology* 25 (58), 1843–1846.
- Friedman, A., Potulska, A., 2001. Quantitative assessment of parkinsonian sialorrhoea and results of treatment with botulinum toxin. *Parkinsonism Relat. Disord.* 7, 329–332.
- Giladi, N., Honigman, S., 1997. Botulinum toxin injections to one leg alleviate freezing of gait in a patient with Parkinson's disease. *Mov. Disord.* 12, 1085–1086.
- Giladi, N., Meer, J., Honigman, S., 1994. The use of botulinum toxin to treat "striatal" toes. *J. Neurol. Neurosurg. Psychiatry* 57, 659.
- Giladi, N., Gurevich, Shabtai H., Paleacu, D., Simon, E.S., 2001a. The effect of botulinum toxin injections to the calf muscles on freezing of gait in parkinsonism: a pilot study. *J. Neurol.* 248, 572–576.
- Giladi, N., McDermott, M.P., Fahn, S., Przedborski, S., Jankovic, J., Stern, M., Tanner, C. the Parkinson Study Group, 2001b. Freezing of gait in PD. Prospective assessment of the DATATOP cohort. *Neurology* 56, 1712–1721.
- Girlanda, P., Quartarone, A., Sinicropi, S., Nicolosi, C., Messina, C., 1996. Unilateral injection of botulinum toxin in blepharospasm: single fiber electromyography and blink reflex study. *Mov. Disord.* 11, 27–31.
- Gupta, A.K., Bluhm, R., Cooper, E.A., Summerbell, R.C., Batra, R., 2003. Seboreic dermatitis. *Dermatol. Clin.* 21, 401–412.
- Gurevich, T., Peretz, C., Moore, O., Weizmann, N., Giladi, N., 2007. The effect of injecting botulinum toxin type A into the calf muscles on freezing of gait in Parkinson's disease: a double blind placebo-controlled pilot study. *Mov. Disord.* 22, 880–883.
- Hallett, M., Evinger, C., Jankovic, J., Stacy, M., 2008. Update on blepharospasm. Report from BEBRF International Workshop 2006. *Neurology* 71, 1275–82.
- Hellmann, M.A., Djaldetti, R., Israel, Z., Melamed, E., 2006. Effect of deep brain subthalamic stimulation on camptocormia and postural abnormalities in idiopathic Parkinson's disease. *Mov. Disord.* 21, 2008–2010.
- Henderson, J.M., Ghika, J.A., Van-Melle, G., Haller, E., Einstein, R., 1996. Botulinum toxin A in nondystonic tremors. *Eur. Neurol.* 36, 29–35.
- Herting, B., Wunderlich, S., Glocker, T., et al., 2004. Computed tomographically-controlled injection of botulinum toxin into the longus colli muscle in severe anterocollis. *Mov. Disord.* 19, 588–590.
- Hirota, N., Hirota, M., Mezaki, T., 1 Mar 2008. Dystonic frowning without blepharospasm. *Parkinsonism Relat. Disord.* [Epub ahead of print].
- Hunker, C.J., Abbs, J.H., 1990. Uniform frequency of parkinsonian resting tremor in the lips, jaw, tongue and index finger. *Mov. Disord.* 5, 71–77.
- Inoue, K., Rogers, J.D., 2007. Botulinum toxin injection into Riolan's muscle: somatosensory 'trick'. *Eur. Neurol.* 58, 138–141.
- Jankovic, J., Orman, J., 1987. Botulinum A toxin for cranial-cervical dystonia: a double-blind, placebo-controlled study. *Neurology* 37, 616–623.
- Jankovic, J., Schwartz, K., 1991. Botulinum toxin treatment of tremors. *Neurology* 41, 1185–1188.
- Jankovic, J., Stacy, M., 2007. Medical management of levodopa-associated motor complications in patients with Parkinson's disease. *CNS Drugs* 21, 677–692.
- Jankovic, J., Tintner, R., 2001. Dystonia and parkinsonism. *Parkinsonism Relat. Disord.* 8, 109–121.
- Jankovic, J., Schwartz, K., Clemence, W., Aswad, A., Mordaunt, J., 1996. A randomized double-blind, placebo controlled study to evaluate botulinum toxin A in essential hand tremor. *Mov. Disord.* 11, 250–256.
- Jankovic, J., Schwartz, K.S., Ondo, W., 1999. Re-emergent tremor of Parkinson's disease. *J. Neurol. Neurosurg. Psychiatry* 67, 646–650.
- Jankovic, J., Hunter, C., Dolimbek, B.Z., Dolimbek, G.S., Adler, C.H., Brashear, A., Comella, C.L., Gordon, M., Riley, D.E., Sethi, K., Singer, C., Stacy, M., Tarsy, D., Atassi, M.Z., 2006. Clinico-immunologic aspects of botulinum toxin type B treatment of cervical dystonia. *Neurology* 67, 2233–2235.
- Jankovic, J., Albanese, A., Atassi, M.Z., Dolly, J.O., Hallett, M., Mayer, N., 2008. Botulinum and Other Neurotoxins: Translating Science into Therapeutic Applications. Butterworth-Heinemann/Elsevier, Philadelphia, PA.
- Jankovic, J., 1995. Apraxia of lid opening. *Mov. Disord.* 10, 686.
- Jankovic, J., 2004. Botulinum toxin in clinical practice. *J. Neurol. Neurosurg. Psychiatry* 75, 951–957.
- Jankovic, J., 2005. Motor fluctuations and dyskinesias in Parkinson's disease: clinical manifestations. *Mov. Disord.* 20 (Suppl. 1), S11–S16.
- Jankovic, J., 2006a. Botulinum toxin therapy for cervical dystonia. *Neurotox. Res.* 9, 145–148.
- Jankovic, J., 2006b. Treatment of dystonia. *Lancet Neurol.* 5, 864–872.
- Jankovic, J., 2008. Parkinson's disease: clinical features and diagnosis. *J. Neurol. Neurosurg. Psychiatry* 79, 368–376.
- Johnston, B.T., Colcher, A., Li, Q., Gideon, R.M., Castell, J.A., Castell, D.O., 2001. Repetitive proximal esophageal contractions: a new manometric finding and a possible further link between Parkinson's disease and achalasia. *Dysphagia* 16, 186–189.
- Jost, W.H., 1999. Treatment of drooling in Parkinson's disease with botulinum toxin. *Mov. Disord.* 14, 1057.
- Kenney, C., Jankovic, J., 2008. Botulinum toxin in the treatment of blepharospasm and hemifacial spasm. *J. Neural. Transm.* 115, 585–591.
- Krack, P., Marion, M.H., 1994. 'Apraxia of lid opening.' A focal eyelid dystonia: clinical study of 32 patients. *Mov. Disord.* 9, 610–615.
- Kuo, S.H., Kenney, C., Jankovic, J., 2008. Bilateral pedunculopontine nuclei stroke presenting as freezing of gait. *Mov. Disord.* 23, 616–619.
- Lagalla, G., Millevolte, M., Capecchi, M., Provinciali, L., Ceravolo, M.G., 2006. Botulinum toxin type A for drooling in Parkinson's disease: a double-blind, randomized, placebo-controlled study. *Mov. Disord.* 21, 704–707.
- Lepore, V., Defazio, G., Acquistapace, D., et al., 1995. Botulinum A toxin for the so-called apraxia of lid opening. *Mov. Disord.* 10, 525–526.
- Lepoutre, A.C., Devos, D., Blanchard-Dauphin, A., Pardessus, V., Maurage, C.A., Ferriby, D., Hurtevent, J.F., Cotten, A., Destee, A., Defebvre, L., 2006. A specific clinical pattern of camptocormia in Parkinson's disease. *J. Neurol. Neurosurg. Psychiatry* 77, 1229–1234.
- Lim, E.C., Seet, R.C., 2008. Botulinum toxin: description of injection techniques and examination of controversies surrounding toxin diffusion. *Acta Neurol. Scand.* 117, 73–84.
- Lipp, A., Trottenberg, T., Schink, T., Kupsch, A., Arnold, G., 2003. A randomized trial of botulinum toxin A for treatment of drooling. *Neurology* 61, 1279–1281.
- Mancini, F., Zangaglia, R., Cristina, S., Sommaruga, M.G., Martignoni, E., Nappi, G., Pacchetti, C., 2003. Double-blind, placebo-controlled study to evaluate the efficacy and safety of botulinum toxin type A in the treatment of drooling in parkinsonism. *Mov. Disord.* 18, 685–688.
- Mathers, S.E., Kempster, P.A., Swash, M., Lees, A.J., 1988. Constipation and paradoxical puborectalis contraction in anismus and Parkinson's disease: a dystonic phenomenon? *J. Neurol. Neurosurg. Psychiatry* 51, 1503–1507.
- Mejia, N.L., Vuong, K.D., Jankovic, J., 2005. Long-term botulinum toxin efficacy, safety and immunogenicity. *Mov. Disord.* 20, 592–597.
- Melamed, E., Djaldetti, R., 2007. Camptocormia in Parkinson's disease. *J. Neurol. Neurosurg. Psychiatry* 78, 1005–1006.
- Molho, E., Jankovic, J., Lew, M., 2008. Role of botulinum toxin in the treatment of cervical dystonia. *Neurol. Clin.* 26 (Suppl. 1), 43–53.

- Molloy, L., 2007. Treatment of sialorrhoea in patients with Parkinson's disease: best current evidence. *Curr. Opin. Neurol.* 20, 493–498.
- Murray, C.A., Cohen, J.L., Solish, N., 2007. Treatment of focal hyperhidrosis. *J. Cutan. Med. Surg.* 11, 67–77.
- Naumann, M., So, Y., Argoff, C.E., Childers, M.K., Dykstra, D.D., Gronseth, G.S., Jabbari, B., Kaufmann, H.C., Schurch, B., Silberstein, S.D., Simpson, D.M., 2008. Therapeutics and Technology Assessment Subcommittee of the American Academy of Neurology. Assessment: botulinum neurotoxin in the treatment of autonomic disorders and pain (an evidence-based review): report of the Therapeutics and Technology Assessment Subcommittee of the American Academy of Neurology. *Neurology* 70, 1707–1714.
- Nóbrega, A.C., Rodrigues, B., Torres, A.C., Enzo, A., Melo, A., 2007. Does botulinum toxin decrease frequency and severity of sialorrhea in Parkinson's disease? *J. Neurol. Sci.* 253, 85–87.
- Ondo, W.G., Hunter, C., Moore, W., 2004. A double-blind placebo-controlled trial of botulinum toxin B for sialorrhea in Parkinson's disease. *Neurology* 62, 37–40.
- Pacchetti, C., Albani, G., Martignoni, E., Godi, L., Alfonsi, E., Nappi, G., 1995. "Off" painful dystonia in Parkinson's disease treated with botulinum toxin. *Mov. Disord.* 10, 333–336.
- Pal, P.K., Calne, D.B., Calne, S., Tsui, J.K., 2000. Botulinum toxin A as treatment for drooling saliva in PD. *Neurology* 54, 244–247.
- Papapetropoulos, S., Baez, S., Zitser, J., Sengun, C., Singer, C., 2007. Retocolitis: classification, clinical phenotype, treatment outcomes and risk factors. *Eur. Neurol.* 59, 71–75.
- Pasricha, P.J., Ravich, W.J., Hendrix, T., et al., 1995. Intrasphincteric botulinum toxin for the treatment of achalasia. *N. Engl. J. Med.* 322, 774–778.
- Patel, A.K., Patterson, J.M., Chapple, C.R., 2006. Botulinum toxin injections for neurogenic and idiopathic detrusor overactivity: a critical analysis of results. *Eur. Urol.* 50, 684–709.
- Pfeiffer, R.F., 2003. Gastrointestinal dysfunction in Parkinson's disease. *Lancet Neurol.* 2, 107–116.
- Pinnington, L.L., Muhiddin, K.A., Ellis, R.E., Playford, E.D., 2000. Non-invasive assessment of swallowing and respiration in Parkinson's disease. *J. Neurol.* 247, 773–777.
- Pohl, D., Tutuian, R., 2007. Achalasia: an overview of diagnosis and treatment. *J. Gastrointest. Liver Dis.* 16, 297–303.
- Proulx de Courval, F.P., Wiseman, M.A., Panisset, M., 2005. Salivary production in Parkinson's disease. *Mov. Disord.* 20, 204–247.
- Pursiainen, V., Haapaniemi, T.H., Korpelainen, J.T., Sotaniemi, K.A., Myllyla, V.V., 2007. Sweating in parkinsonian patients with wearing-off. *Mov. Disord.* 22, 828–832.
- Racette, B.A., Good, L., Sagitto, S., Perlmutter, J.S., 2003. Botulinum toxin B reduces sialorrhea in parkinsonism. *Mov. Disord.* 18, 1059–1061.
- Rieder, C.R., Schestatsky, P., Socal, M.P., Monte, T.L., Fricke, D., Costa, J., Picon, P.D., 2007. A double-blind, randomized, crossover study of prosigine versus botox in patients with blepharospasm and hemifacial spasm. *Clin. Neuropharmacol.* 30, 39–42.
- Roggenkamper, P., Jost, W.H., Bihari, K., Comes, G., Grafe, S. for the NT 201 Blepharospasm Study Team, 2006. Efficacy and safety of a new botulinum toxin type A free of complexing proteins in the treatment of blepharospasm. *J. Neural. Transm.* 113, 303–312.
- Sakakibara, R., Odaka, T., Uchiyama, T., Asahina, M., Yamaguchi, K., Yamaguchi, T., Yamanishi, T., Hattori, T., 2003. Colonic transit time and rectoanal videomanometry in Parkinson's disease. *J. Neurol. Neurosurg. Psychiatry* 74, 268–272.
- Santamato, A., Ianieri, G., Ranieri, M., Megna, M., Panza, F., Fiore, P., Megna, G., 2008. Botulinum toxin type A in the treatment of sialorrhoea in Parkinson's disease. *J. Am. Geriatr. Soc.* 56, 765–767.
- Schestatsky, P., Valls-Sole, J., Ehlers, J.A., Rieder, C.R., Gomes, I., 2006. Hyperhidrosis in Parkinson's disease. *Mov. Disord.* 21, 1744–1748.
- Schiano, T.D., Parkman, H.P., Miller, L.S., et al., 1998. Use of botulinum toxin in the treatment of achalasia. *Dig. Dis.* 16, 14–22.
- Schneider, S.A., Edwards, M.J., Cordivari, C., Macleod, W.N., Bhatia, K.P., 2006. Botulinum toxin A may be efficacious as treatment for jaw tremor in Parkinson's disease. *Mov. Disord.* 21, 1722–1724.
- Sheffield, J.K., Jankovic, J., 2007. Botulinum toxin in the treatment of tremors, dystonias, sialorrhea and other symptoms associated with Parkinson's disease. *Expert Rev. Neurother.* 7, 637–647.
- Simpson, D.M., Blitzer, A., Brashear, A., Comella, C., Dubinsky, R., Hallett, M., Jankovic, J., Karp, B., Ludlow, C.L., Miyasaki, J.M., Naumann, M., So, Y., 2008. Therapeutics and Technology Assessment Subcommittee of the American Academy of Neurology. Assessment: botulinum neurotoxin for the treatment of movement disorders (an evidence-based review): report of the Therapeutics and Technology Assessment Subcommittee of the American Academy of Neurology. *Neurology* 70, 1699–1706.
- Solish, N., Bertucci, V., Dansereau, A., Hong, H.C., Lynde, C., Lupin, M., Smith, K.C., Storwick, G., 2007. A comprehensive approach to the recognition, diagnosis, and severity-based treatment of focal hyperhidrosis: recommendations of the Canadian hyperhidrosis advisory committee. *Dermatol. Surg.* 33, 908–923.
- Soonawala, N., Bhatia, K.P., Yeung, J.H.M., et al., 1999. Idiopathic blepharospasm does not lead to a parkinsonian syndrome: results of a questionnaire-based follow-up study. *J. Neurol.* 246, 283–286.
- Swinn, L., Schrag, A., Viswanathan, R., et al., 2003. Sweating dysfunction in Parkinson's disease. *Mov. Disord.* 18, 1459–1463.
- Tan, E.K., Jankovic, J., 2000. Treating severe bruxism with botulinum toxin. *J. Am. Dent. Assoc.* 131, 211–216.
- Tintner, R., Gross, R., Winzer, U.F., Smalky, K.A., Jankovic, J., 2005. Autonomic function after botulinum toxin type A or B: a double-blind, randomized trial. *Neurology* 65, 765–767.
- Trosch, R.M., Pullman, S.C., 1994. Botulinum toxin A injections for the treatment of hand tremor. *Mov. Disord.* 9, 601–609.
- Truong, D.D., Jost, W.H., 2006. Botulinum toxin: clinical use. *Parkinsonism Relat. Disord.* 12, 331–355.
- Truong, D., Comella, C., Fernandez, H.H., Ondo, W.G., 2008. Dysport Benign Essential Blepharospasm Study Group. Efficacy and safety of purified botulinum toxin type A (Dysport®) for the treatment of benign essential blepharospasm: a randomized, placebo-controlled, phase II trial. *Parkinsonism Relat. Disord.* 4, 407–414.
- Tscheng, D.Z., 2002. Sialorrhoea – therapeutic drug options. *Ann. Pharmacother.* 36, 1785–1790.
- Tumilasci, O.R., Cersosimo, M.G., Belforte, J.E., Micheli, F.E., Benarroch, E.E., Pazo, J.H., 2006. Quantitative study of salivary secretion in Parkinson's disease. *Mov. Disord.* 21, 660–667.
- van de Warrenburg, B.P., Cordivari, C., Ryan, A.M., et al., 2007. The phenomenon of disproportionate antecollic in Parkinson's disease and multiple system atrophy. *Mov. Disord.* 22, 2325–2331.
- von Coelln, R., Raible, A., Gasser, T., Asmus, F., 2008. Ultrasound-guided injection of the iliopsoas muscle with botulinum toxin in camptocormia. *Mov. Disord.* 23, 889–892.
- Wieler, M., Camicioli, R., Jones, C.A., Martin, W.R., 2005. Botulinum toxin injections do not improve freezing of gait in Parkinson disease. *Neurology* 65, 626–628.